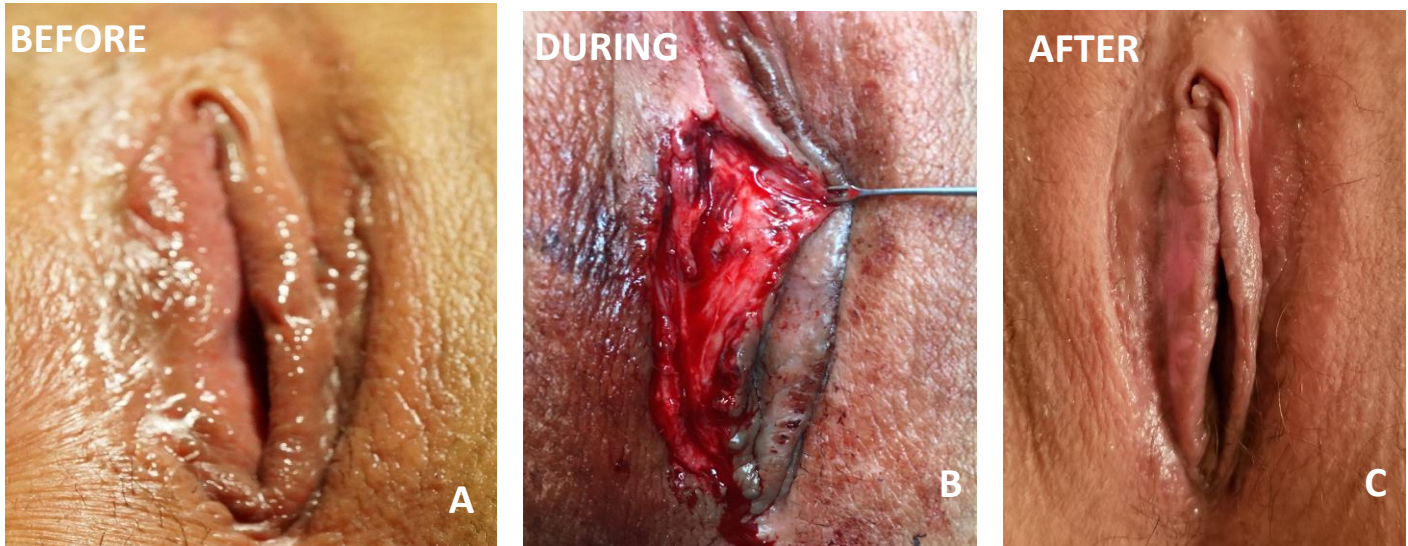


GRAPHICAL ABSTRACT

TITLE: *Labiolysis for labia minora fusion*



Surgeon: *Prof. Dr. Adam Ostrzenski*

Country: *USA*

Medical Complaints: *Severe persistent pain and superficial dyspareunia*

Diagnosis:

A. Fusion of the labia minora — intralabial creases — labia majora followed a trimming labioreduction procedure

Procedure:

B. Labiolysis — to free the labia minora from unnatural fusion

Outcome:

C. Labiolysis established the natural, free edge look, shape, color, symmetry of the labia minora, fully functional, and illness symptoms.